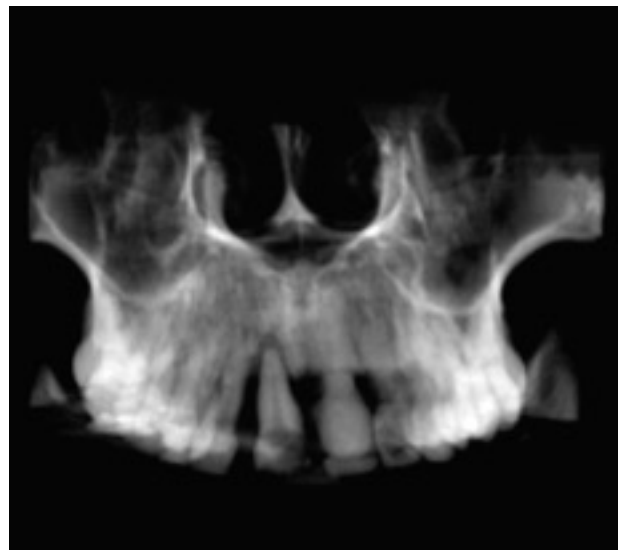
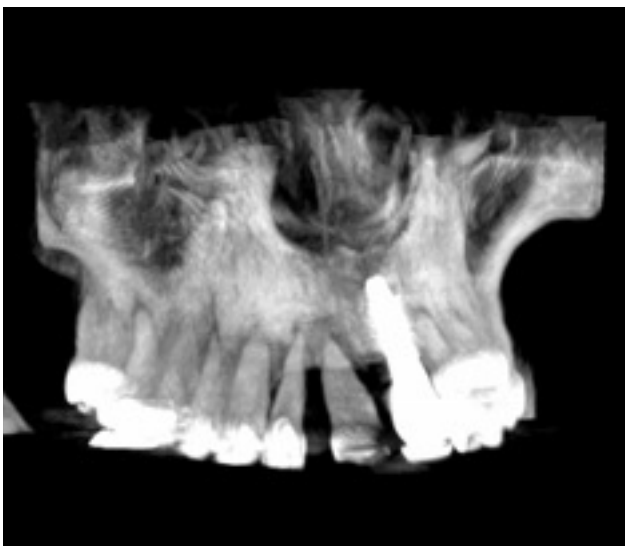
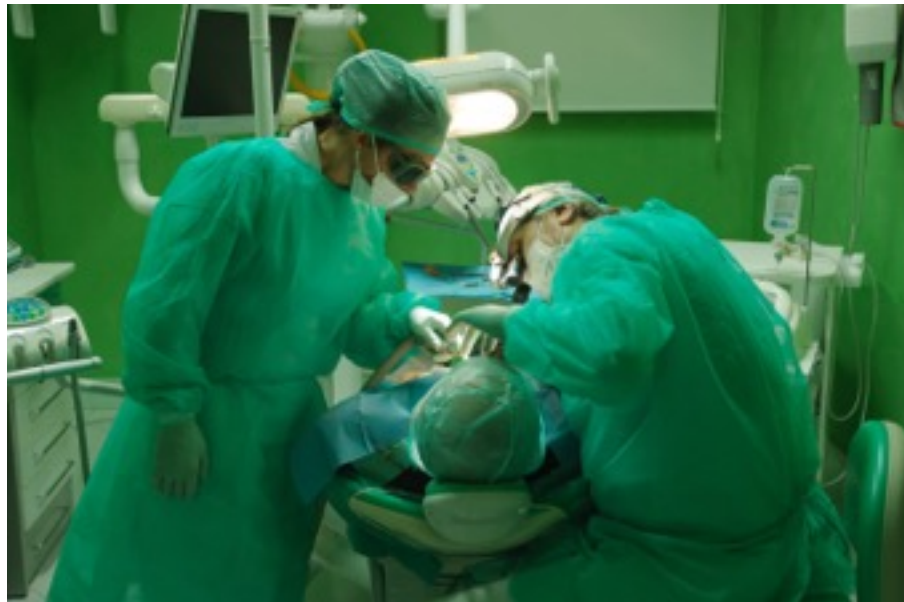
“SpeedyGuide System”

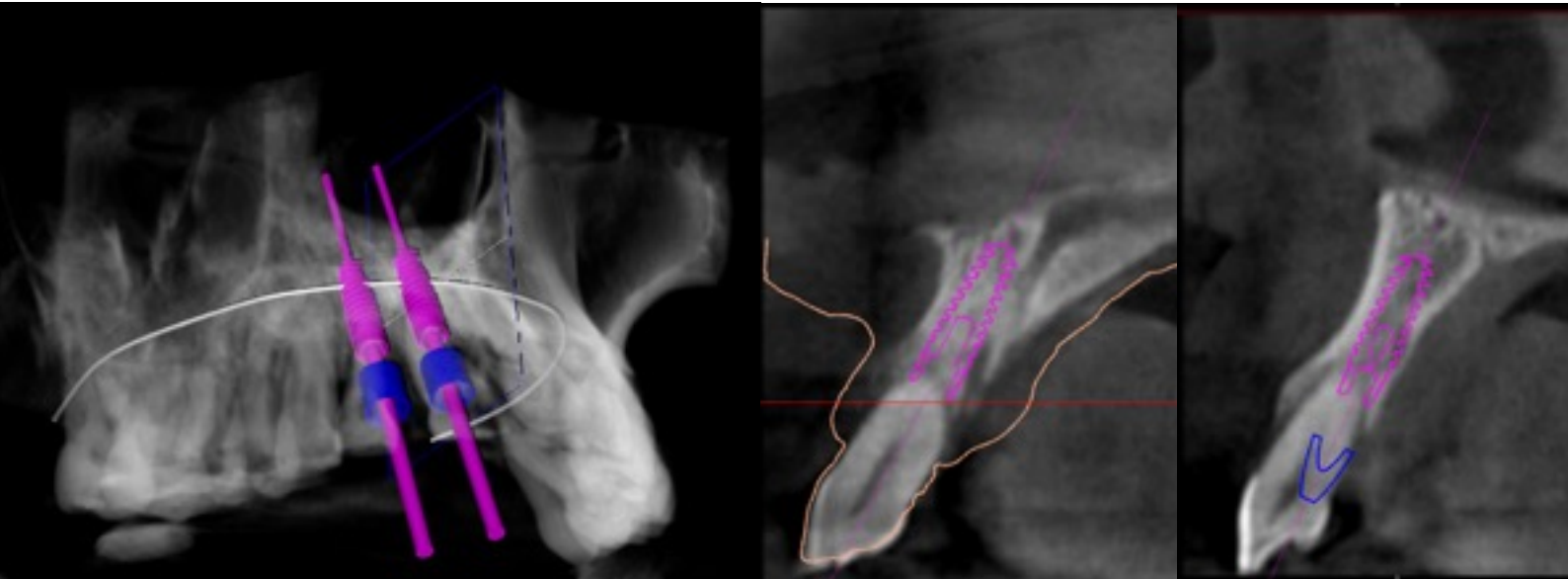
Guided surgery applied to placement of customized bone graft, with contextual insertion of fixtures in post-extraction area with high aesthetic value.

Case Report

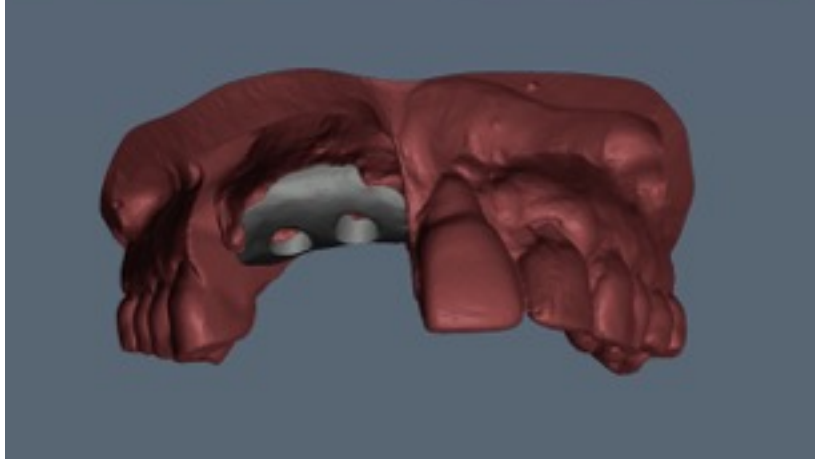
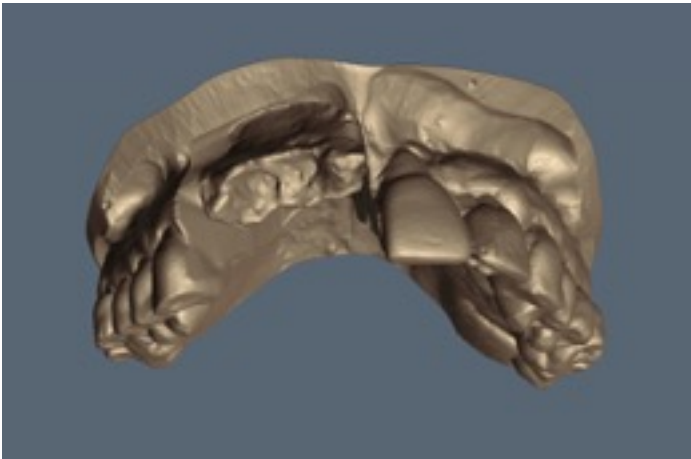
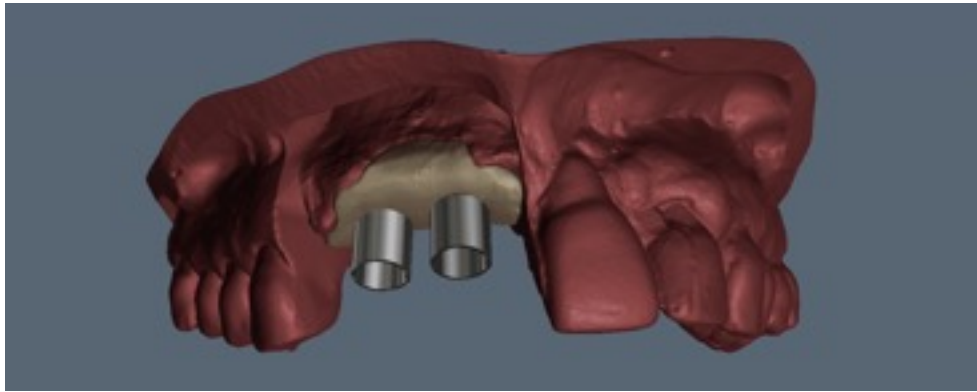
- Female 58 years old
- No systemic diseases
- periodontal disease with bone defect in the area 11-12



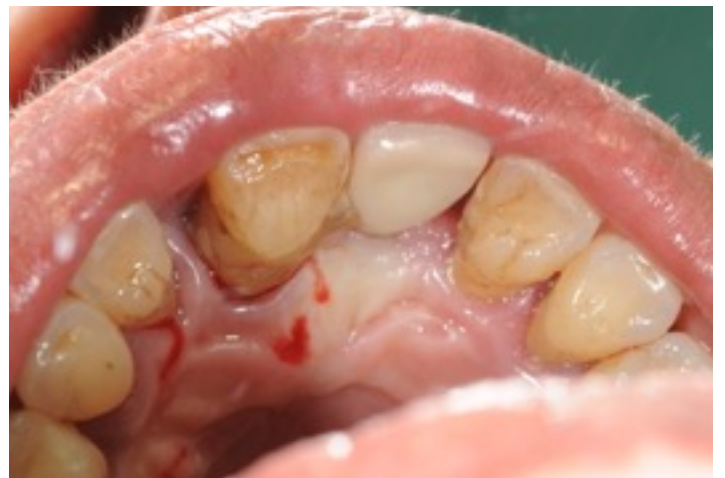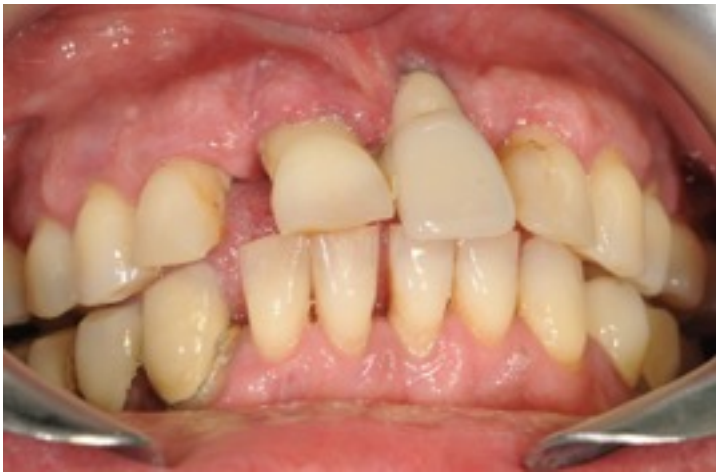“Software Speedy3D “ Planning Axis implants



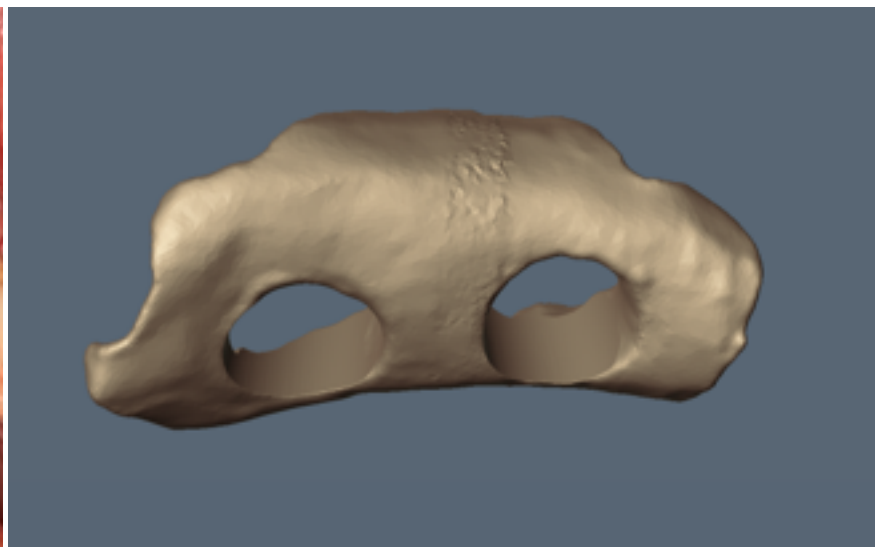
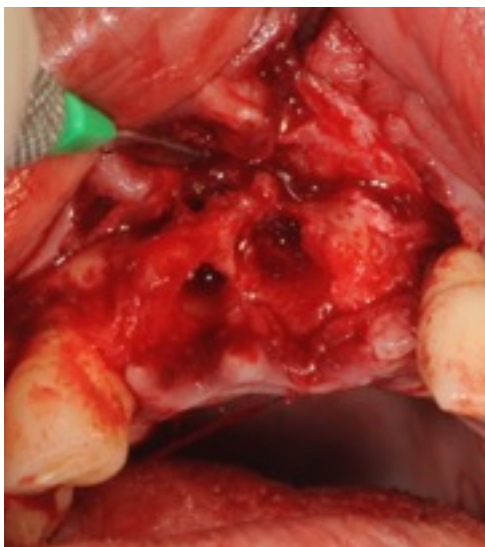
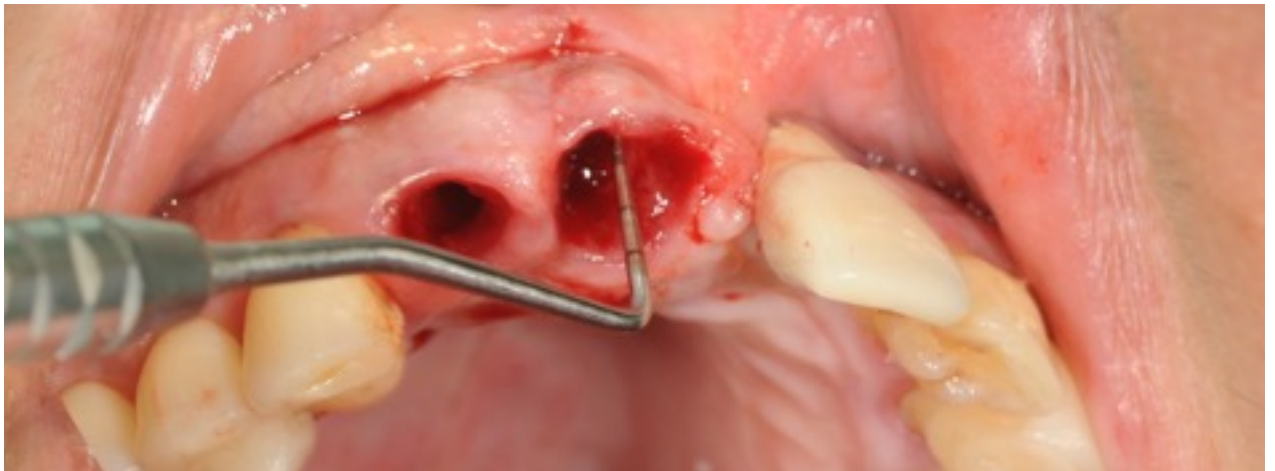
3D modeling of the bone graft



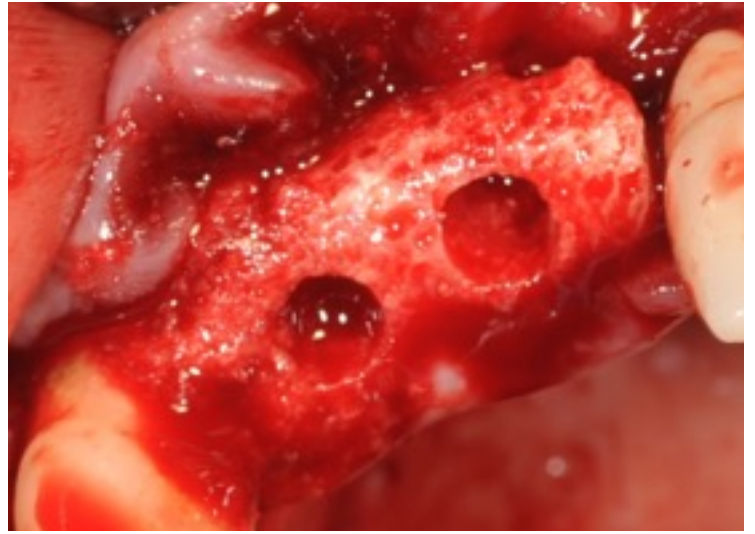
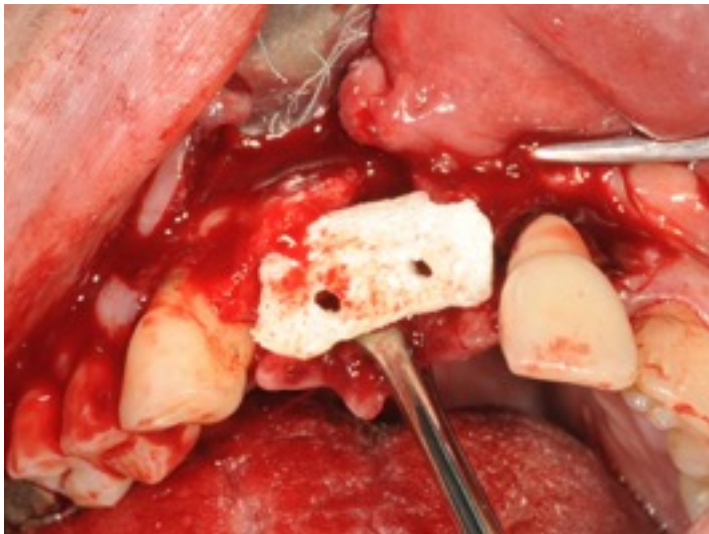Surgery



Teeth extraction and flap surgery

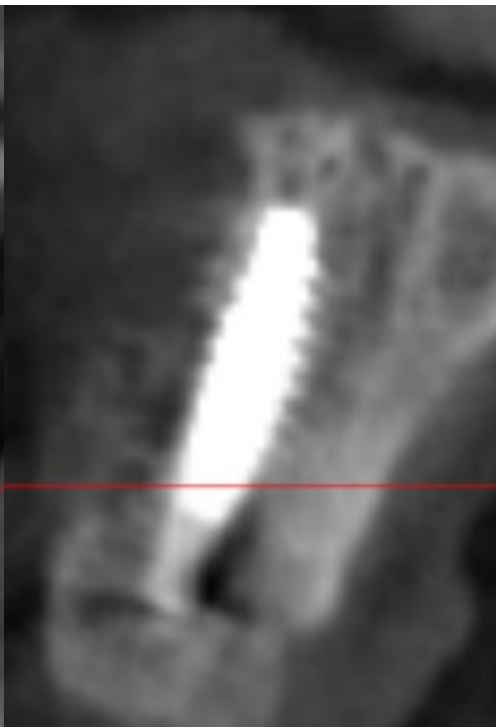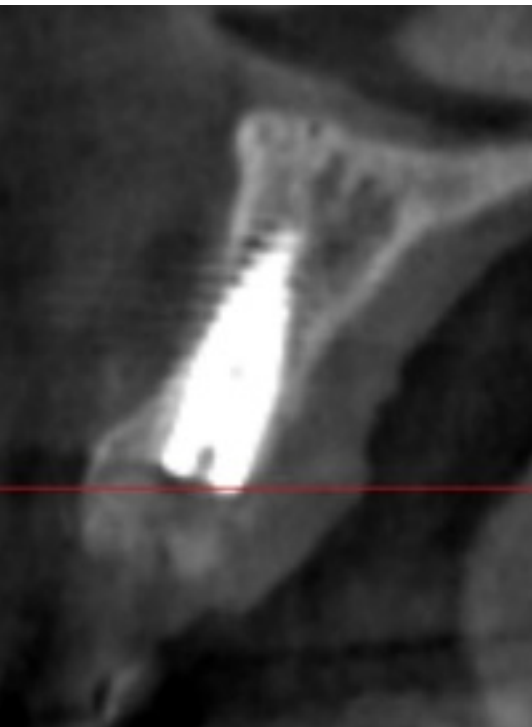
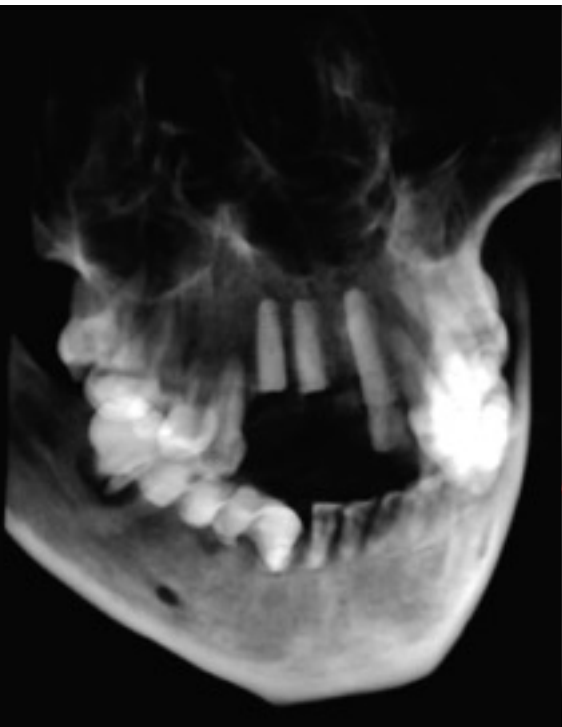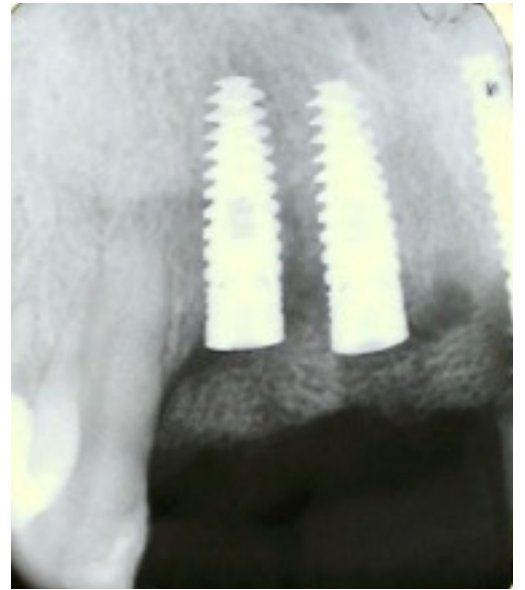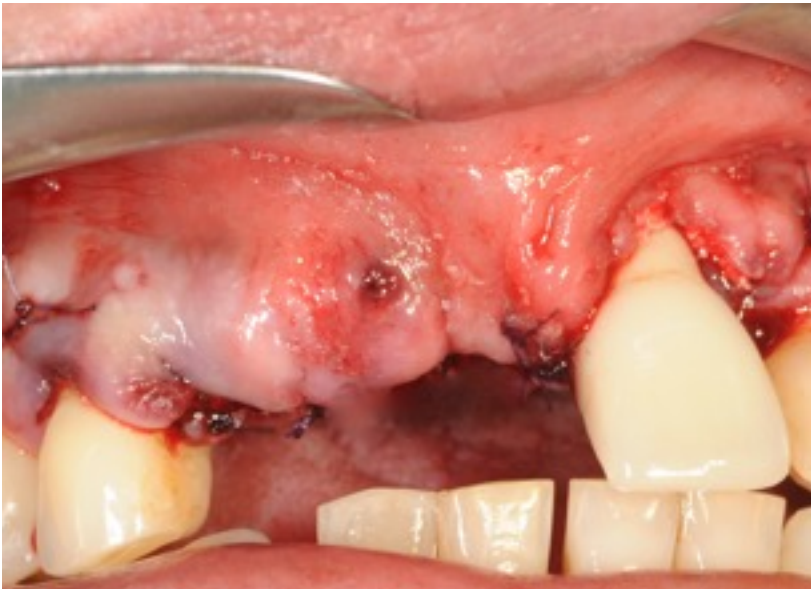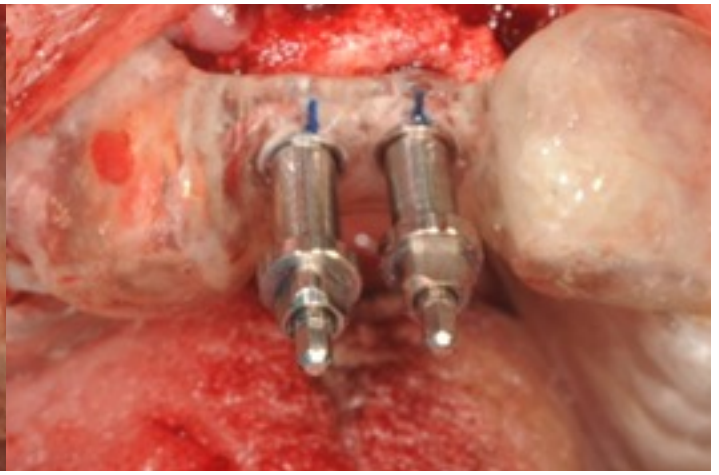
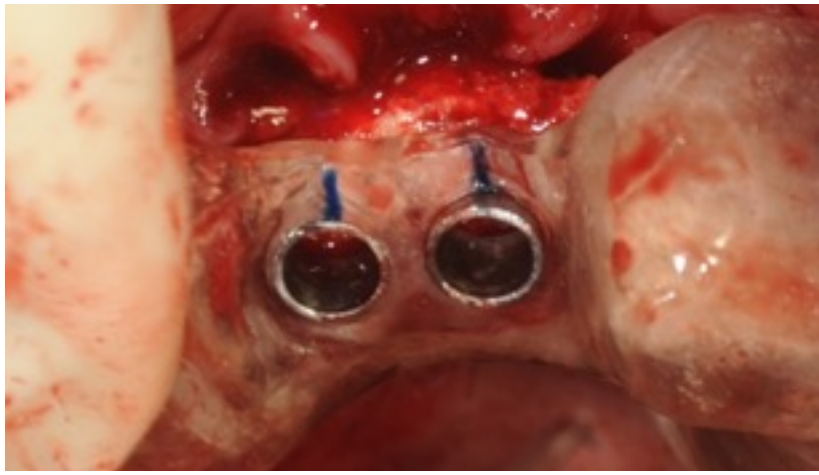


Bone graft placement



Guided insertion of fixtures Axis 3,75x13





Dr. Luca Nobili



Piombino (Livorno) Italy



